Pauses and Their Connection to the P-P Intervals
Part 1

Jerry W. Jones, MD

Often we come upon pauses on 12-lead ECGs and rhythm strips. Some of these pauses have durations that we are simply unable to justify while others are easier to comprehend. In this article I want to discuss how to better understand these pauses.

Compensatory Pauses

Let's look at a very simple example: a *compensatory pause*…

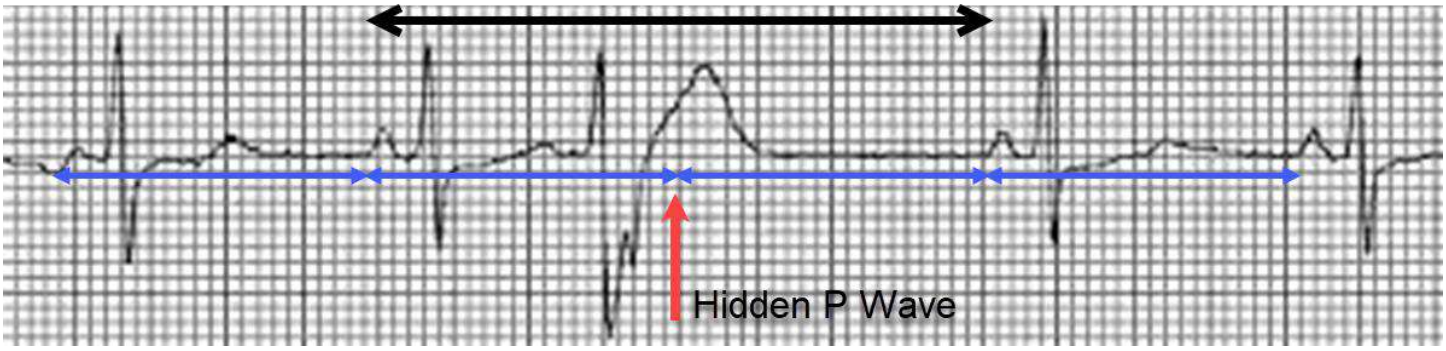

Figure 1

This is a very common finding in electrocardiography. In this type of pause, we should remain focused on the P waves… *not* the QRS complexes. There are two intervals in particular that we should study very carefully: 1) a normal P-P interval, and 2) the interval from the first P wave *before* the ectopic beat to the first *conducted* P wave *following* the ectopic beat. There is no specific name for this last interval, so let's call it the ***inclusive P-P interval***. The P-P interval *before* the PVC and the P-P interval that *follows* the PVC are equal. This *inclusive P-P interval* (black double-headed arrow) is equal to TWO regular P-P intervals. What does that tell us?

When there is no apparent interruption of the sinus rhythm, that means that the ectopic beat – in this case, the PVC – *did not reach the atrium*. The sinus node was able to discharge on time. Unfortunately, we can't see the P wave it produced because it is hidden within the T wave of the PVC. We can, however, see the next *conducted* P wave produced by the sinus node and it is right on time. So, a *compensatory pause* tells us that there was *no effect on the sinus node* by the ectopic beat. We say it is a *compensatory* pause because the pause allows the P waves to continue appearing right on time.

Non-Compensatory Pauses

As the term implies, this is not a pause that will keep the P waves appearing on-time. There is a premature ectopic beat that will upset the rhythm of the sinus node and cause the next sinus P wave to appear "out of sync." Here is an example:

Figure 2

In this rhythm strip, we see a premature atrial complex (PAC) with an *inclusive* P-P interval that is *longer* than the regular P-P interval, but *shorter* than *two* regular P-P intervals.

Remember, a *compensatory* pause is created by adding one regular P-P interval to a second regular P-P interval.

With a *non-compensatory* pause, we have two possibilities:

1. a *coupling interval* **+** a regular P-P interval, or…
2. a *coupling interval* **+** a short delay **+** a regular P-P interval.

A *coupling interval* is the interval from a sinus-conducted deflection to a following ectopic deflection of the same type. In this case, it's the interval from the sinus-conducted P wave to the P' wave of the PAC (red arrow in Figure 2). (P' = P wave originating outside the sinus node)

Let's make some measurements…

Figure 3

The blue arrows are equal to the inclusive P-P interval. As you can see by the blue arrow on the upper right, it is LESS than two regular P-P intervals. The next question: does this represent just the coupling interval + a regular P-P interval, or a coupling interval + a short delay + a regular P-P interval?

We will decide this by measuring back one regular P-P interval from the sinus-conducted P wave that follows the PAC (red arrow in Figure 3). We measure *the delay* from the onset of the ectopic beat (in this case, the P' of the PAC) to the point at which we *presume* the sinus node has restarted its spontaneous depolarization. And we found that point by *measuring back one regular P-P interval*.

Now let's review what we did in a systematic manner…

1. We *noted the coupling interval* (in this case, from the sinus P wave to the P').
2. We then wanted to know: *at which point did the sinus node start depolarizing again?* We determined this by measuring back one regular P-P interval from the sinus P wave that ends the inclusive P-P interval (backward-pointing red arrow in Figure 3).
3. When there has been no delay, this point will coincide with the ectopic beat (or nearly so). Any separation between the ectopic beat and the beginning of the regular P-P interval indicates a *delay*. In Figure 3, you can see the separation (**B**) between the red backward-pointing arrow indicating the presumed beginning of sinus depolarization, and the ectopic beat.

OK… we see that the inclusive P-P interval PAC is composed of the *coupling interval* (**A**), a *short delay* (**B**), and a *regular P-P interval* (**C**).

Because a coupling interval is *always* terminated by a *premature* beat, it will *always* be less than a regular P-P interval. Therefore, it's easy to understand why a *non-compensatory* pause composed of just a *coupling interval* and one *regular P-P interval* will always be less than two regular P-P intervals. When an inclusive P-P interval is composed only of a coupling interval and a regular P-P interval, it is presumed that the ectopic beat *immediately* reset the sinus node which then restarted its spontaneous depolarization *without delay*.

But in this example, there *is* a short delay! What caused that delay?

In most cases, when an ectopic impulse is successful in entering the sinus node and resetting it, it usually takes it back down close to its resting membrane potential (RMP) of about -60 mV. But sometimes the reset takes the RMP to more negative levels. It then takes more time for the RMP to *return to its normal level* and *resume its spontaneous depolarization*. In this particular example, even though there was a short delay, the inclusive P-P interval was still *shorter* than two regular P-P intervals.

But, what if the PAC had hyperpolarized the sinus node to a *much* more negative level? That happens occasionally, and in those cases, the *coupling interval* + the *depolarization delay* + the *regular P-P interval* can be significantly LONGER than two P-P intervals. Regardless, it is still a ***non-compensatory pause****!* Non-compensatory pauses are usually *shorter* than two regular P-P intervals… but they CAN be *longer!*

This is basic information to prepare you for the next installment (Part 2) which will deal with pauses during ectopic rhythms. The concepts you will learn in Part 2 will be much easier to understand with the knowledge you acquired today!

To learn more about improving your ECG interpretation skills, please visit:

https://medicusofhouston.com

"When someone's life is in your hands…

…you need more than just introductory-level knowledge and skills!"

Jerry W. Jones, MD